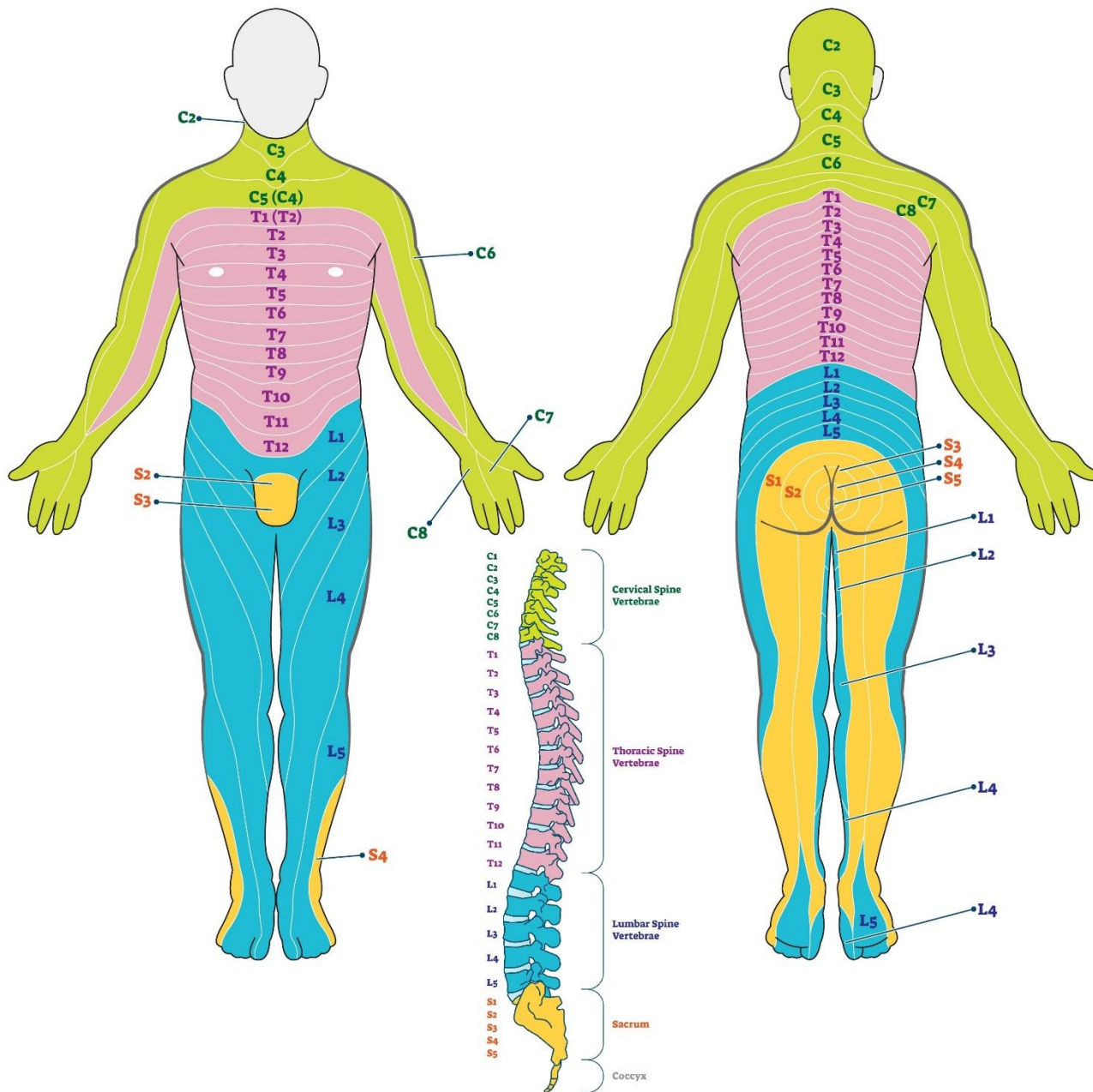


Dermatome

A **dermatome** is an area of the skin that is mainly supplied by a single spinal nerve. Each of these nerves relay sensation (including pain) from a particular region of skin to the brain. Dermatomes are useful to help localize neurologic levels, particularly in radiculopathy.



Levels of Principal Dermatomes

C5	Clavicles	T10	Level of umbilicus
C5, C6, C7	Lateral parts of upper limbs	T12	Inguinal or groin regions
C8, T1	Medial sides of upper limbs	L1, L2, L3, L4	Anterior and inner surfaces of lower limbs
C6	Thumb	L4, L5, S1	Foot
C6, C7, C8	Hand	L4	Medial side of great toe
C8	Ring and little fingers	L5, S1, S2	Outer and posterior sides of lower limbs
T4	Level of nipples	S1	Lateral margin of foot and little toe
		S2, S3, S4	Perineum

Schematic demarcation of dermatomes shown as distinct segments. There is considerable overlap between any two adjacent dermatomes.

References:

- Standing S, Gray H. *Grey's Anatomy of the Human Body*. 39th ed. Philadelphia, Pa: Lea & Febiger; 2005. 435-7.
- Stephen Kishner, M. (2023, June 5). Dermatomes Anatomy. Overview, Gross Anatomy, Natural Variants. <https://emedicine.medscape.com/article/1878388-overview?form=fpf>